


LESSON 1:

Planes of Dissection and Directional Terms




Planes of dissection

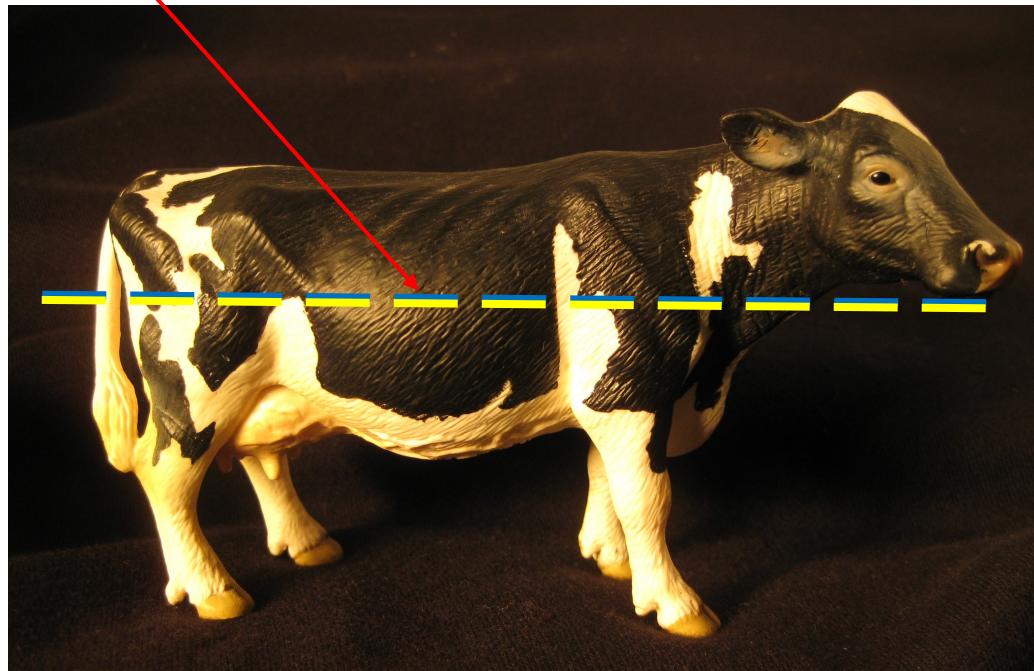
Median plane




Median plane




Dorsal plane



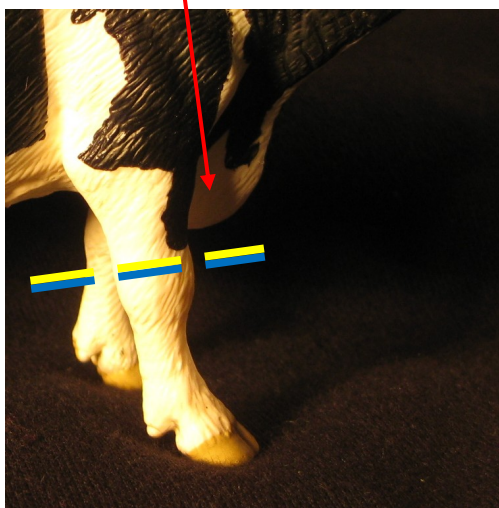
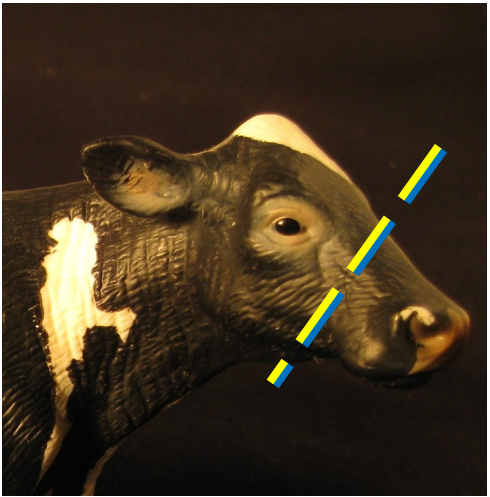
Dorsal plane



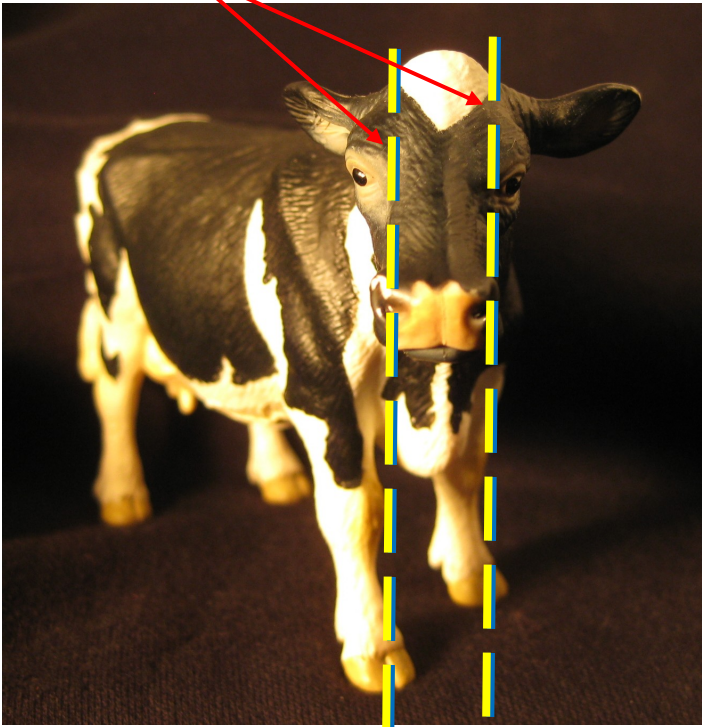
Transverse planes



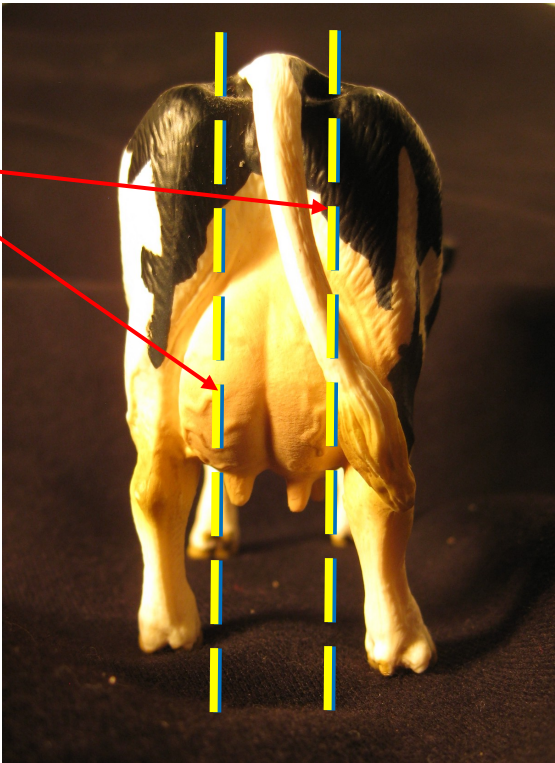
Transverse planes



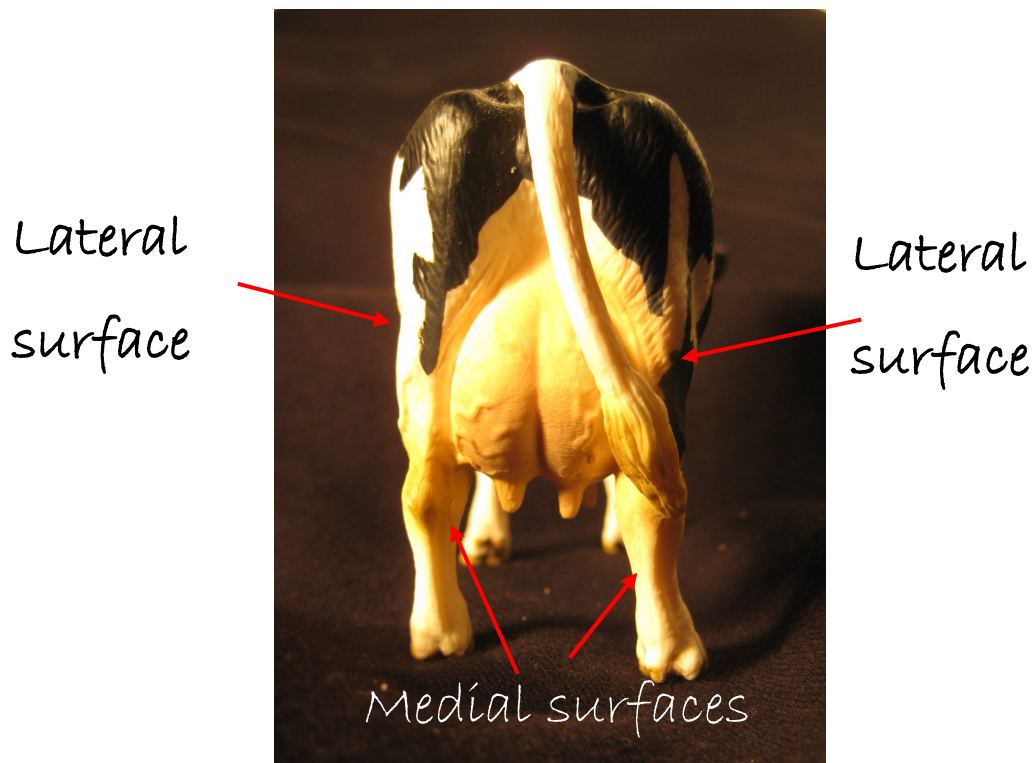
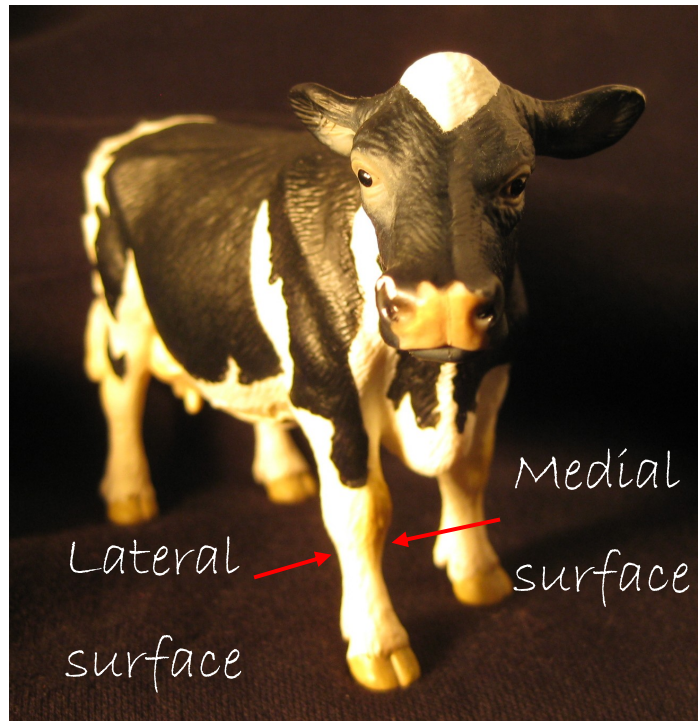
Sagittal planes




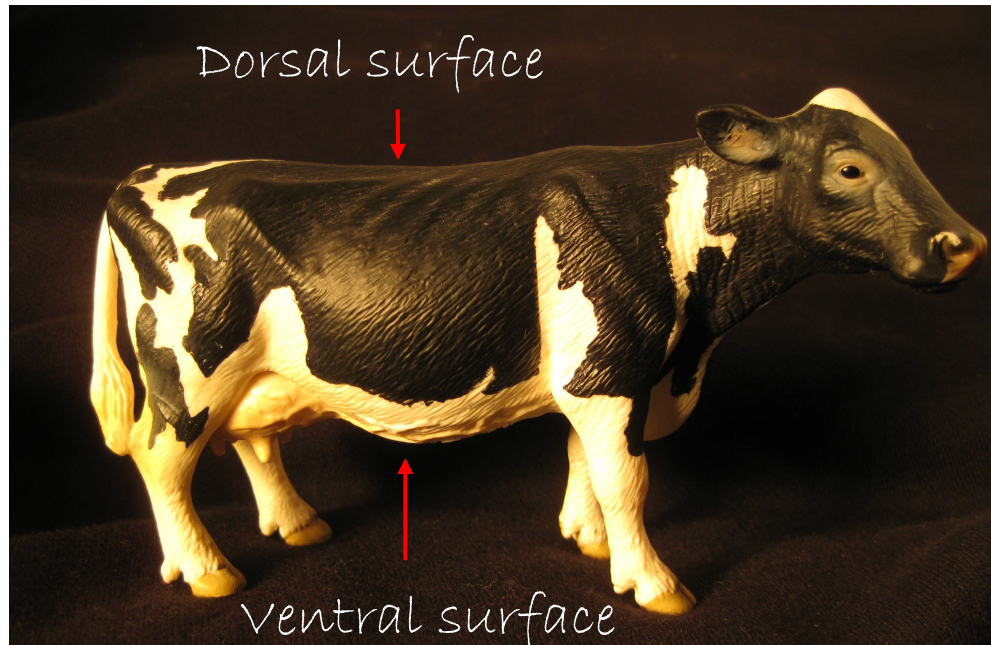
Sagittal planes



Directional terms: Medial vs. Lateral




Directional terms: Dorsal vs. Ventral




Directional terms: Cranial vs. Caudal

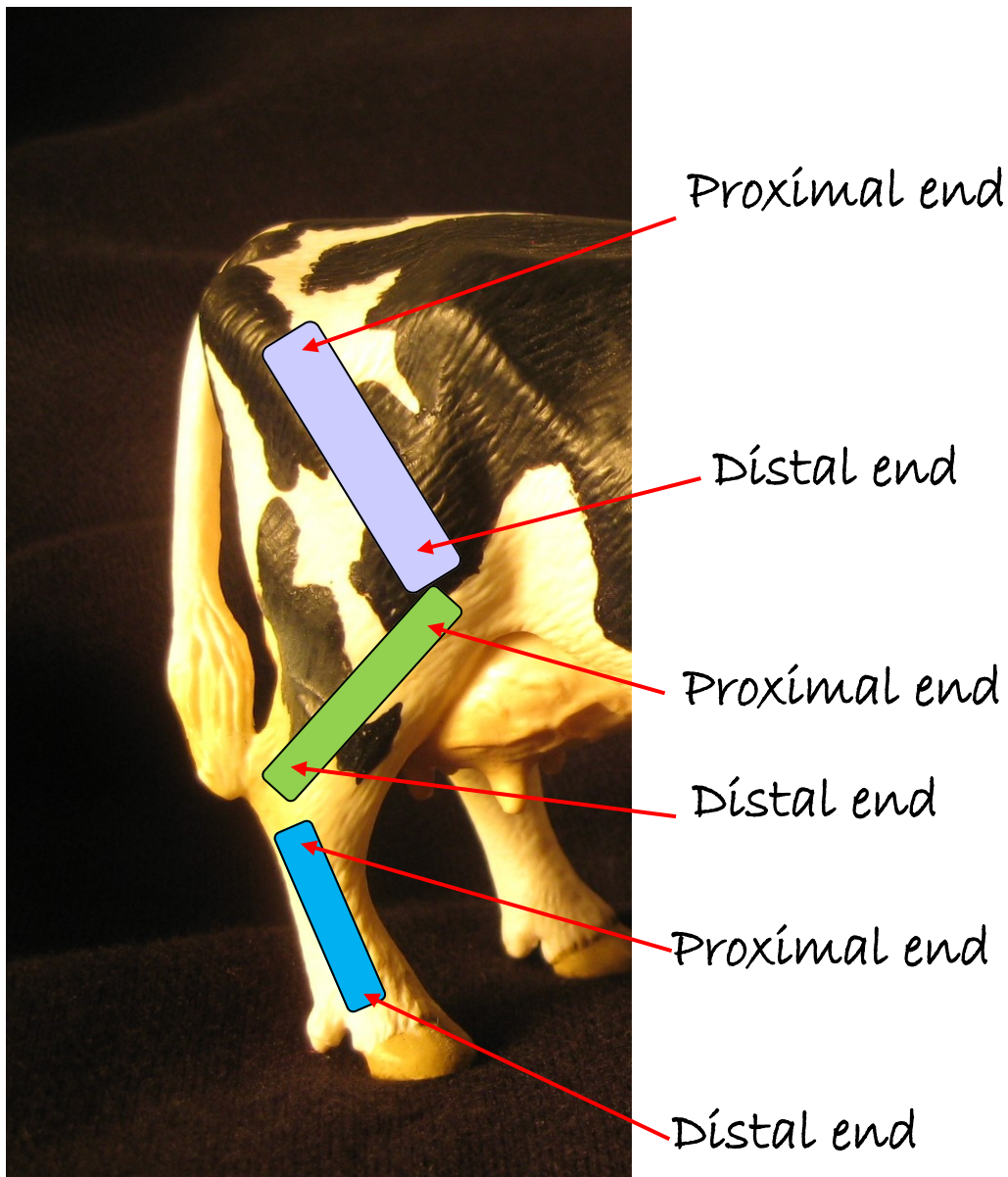
Cranial direction



Caudal direction




Directional terms: Proximal vs. Distal

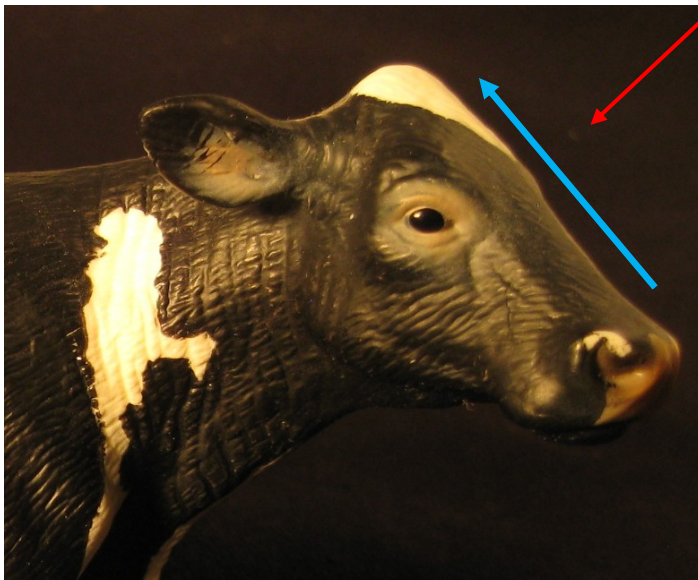


Directional terms: Rostral vs. Caudal

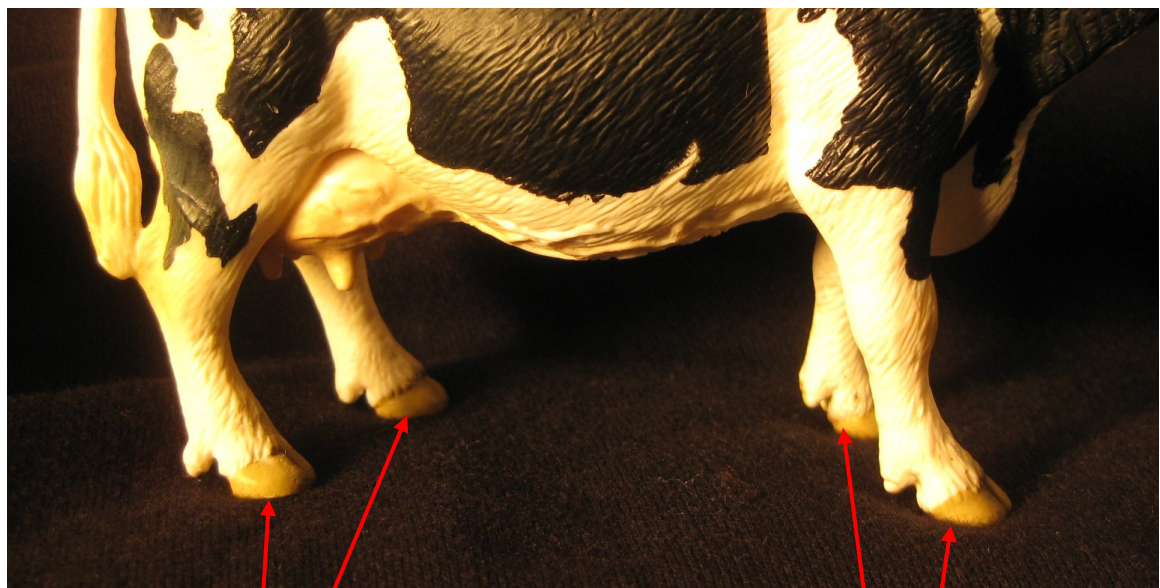
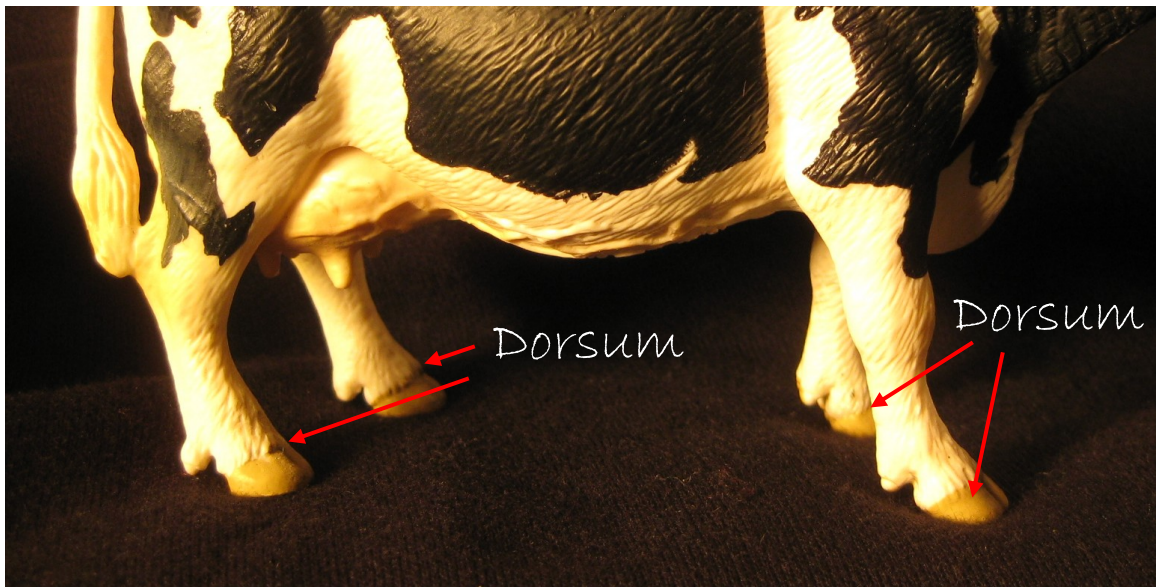
Rostral direction



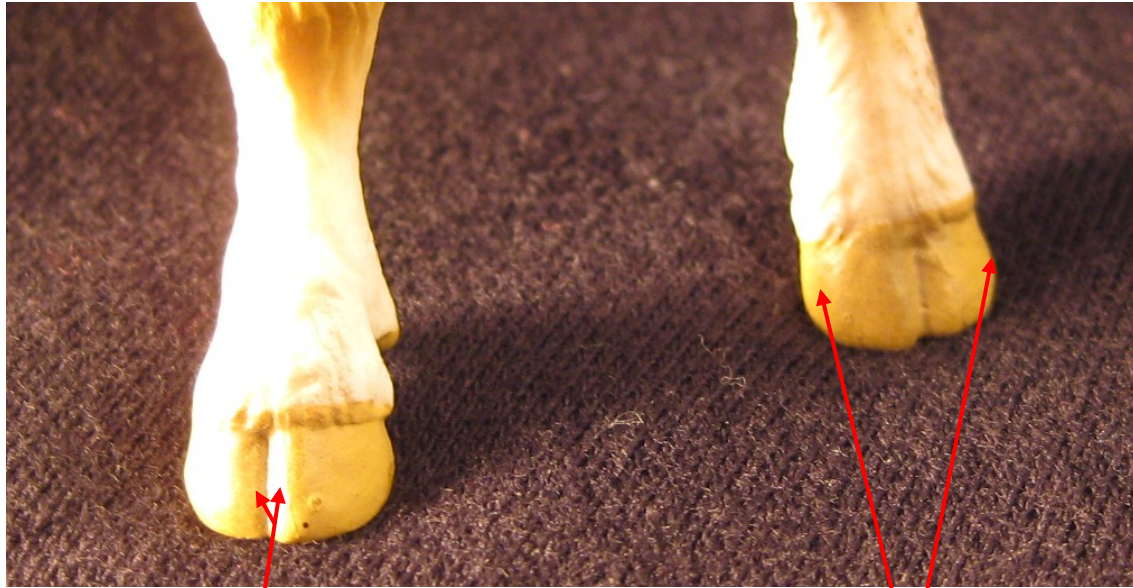Caudal direction



Directional terms: Dorsum vs. Palmar and Plantar



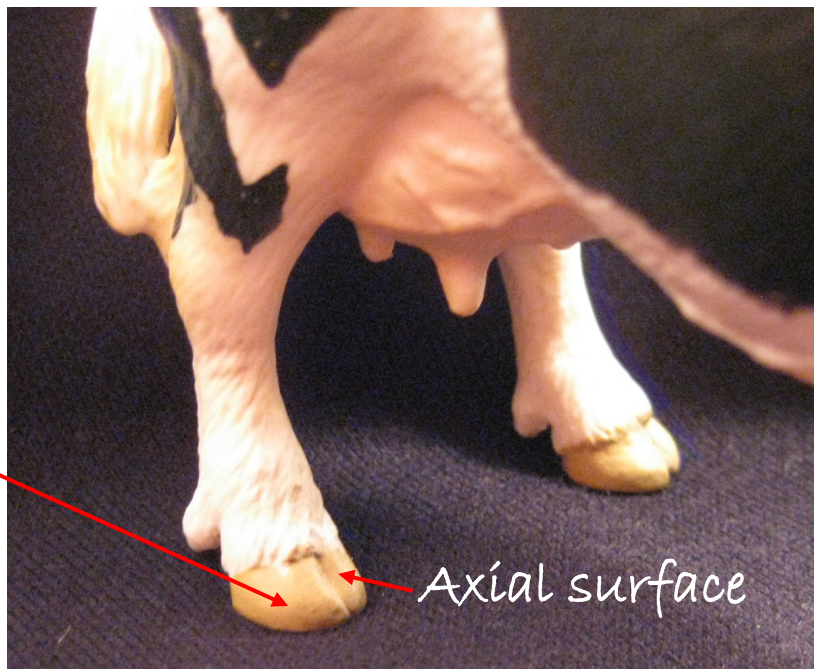Directional terms: Axial vs. Abaxial



Axial surfaces

Abaxial surfaces


Abaxial surface



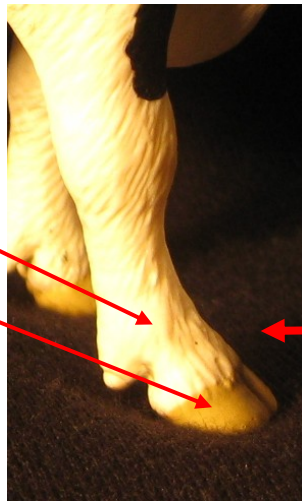Axial surface

Directional terms: Superficial vs. Deep

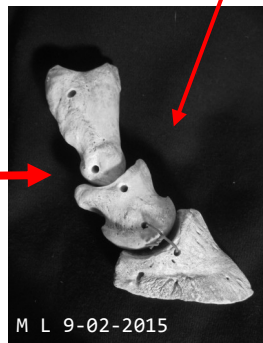
Superficial—closer to the surface.



Superficial structures (skin and hoof)

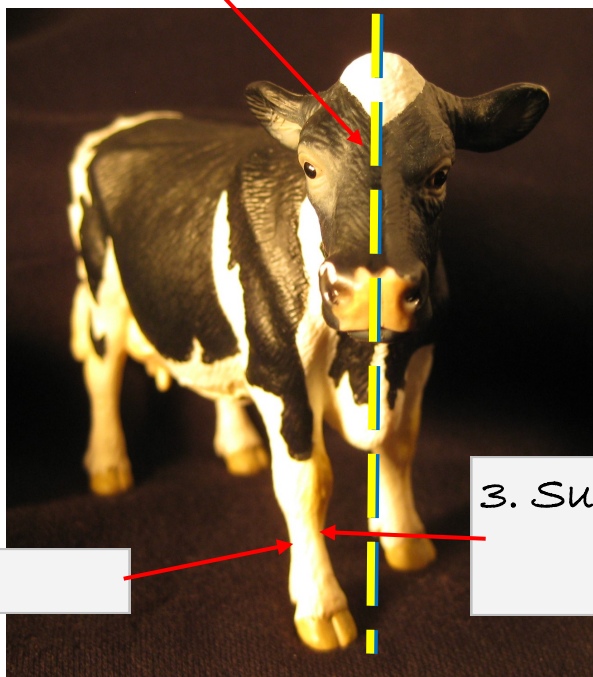


Deep structures (bones)



Lesson 1 Assessment

1. Plane:




2. Surface:

3. Surface:

4. Plane:

5. Direction:



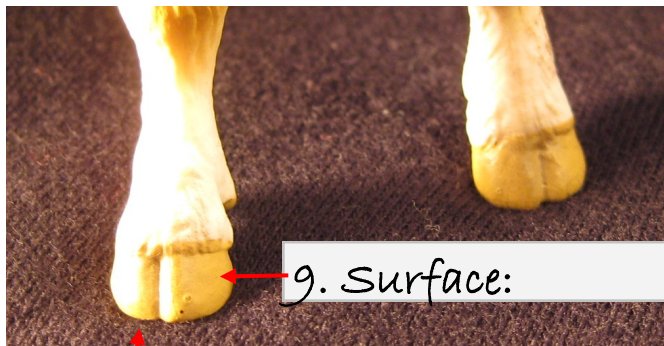

6. Surface:

7. Surface:

MORE 

Lesson 1 Assessment (continued)

8. Direction:



9. Surface:

10. Surface (beneath front foot):


11. Plane:

12. Surface:

13. End:

14. End:

15. Direction:



Notes